

Disease Surveillance and Investigation Branch

# DISEASE SURVEILLANCE REPORT

## Northern Ireland Disease Surveillance Report, January to March 2018

- Pneumonia and otitis media caused by *Mycoplasma bovis* in cattle
- Anaphylaxis in cattle
- Mycotic infections in cattle and sheep
- Schmallenberg virus in cattle and sheep
- Johne's disease in sheep

These are some of the matters discussed in the Northern Ireland animal disease surveillance quarterly report for 1st January to 31st March 2018

### CATTLE:

#### Respiratory diseases

Respiratory disease was identified in 67 cattle post mortem submissions between January and March 2018. The most common pathogens identified included *Mycoplasma bovis* (twenty four cases), *Mannheimia haemolytica* (eleven cases), *Pasteurella multocida* (seven cases), *Trueperella pyogenes* (four cases) and *Histophilus somni* (two cases).

#### Pneumonia due to *Mycoplasma bovis* with otitis media

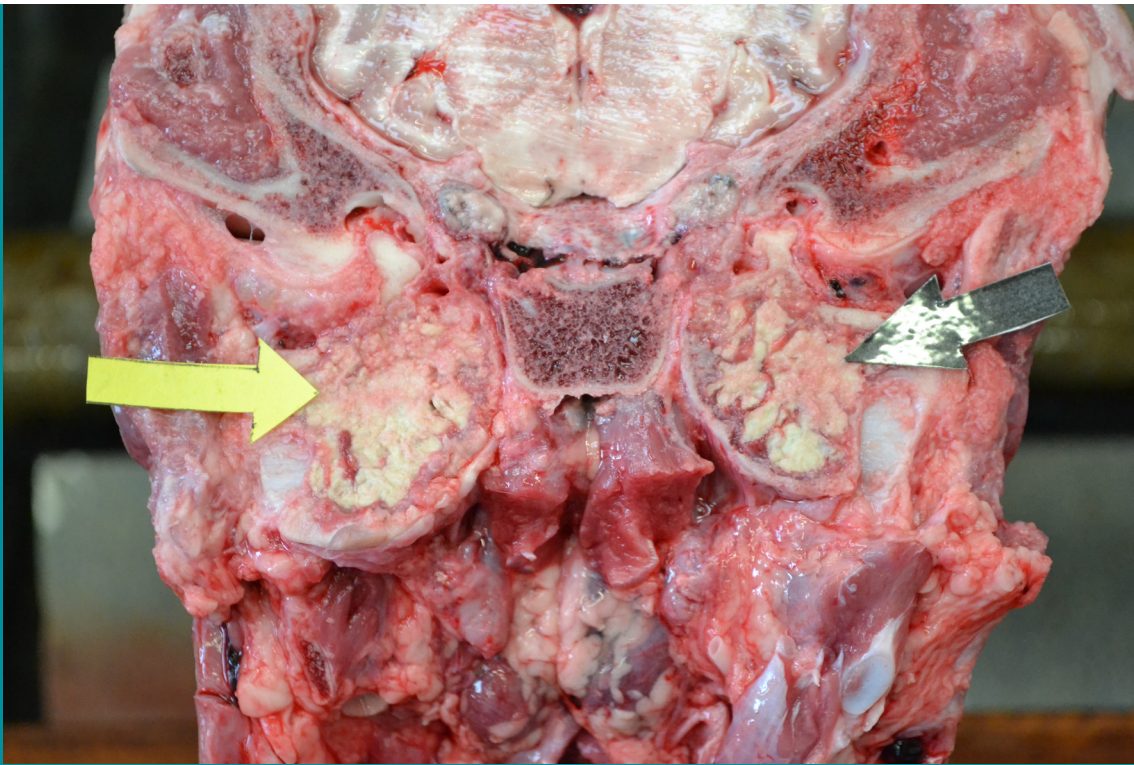
Three cases of pneumonia due to *Mycoplasma bovis* accompanied by otitis media were diagnosed during the quarter. In one case affecting a five month old calf there was severe pneumonia with red purple consolidation of anteroventral lung and miliary foci of caseous necrosis. Histologically lung lesions were suggestive of *Mycoplasma bovis* infection. There was thick yellow caseous material bilaterally in the tympanic bullae. *Mycoplasma bovis* was detected by PCR in both lung and middle ear material. As well as having received treatment for respiratory signs the calf had developed a head tilt. In a separate case of pneumonia and otitis media due to *Mycoplasma bovis*, BVDV was detected as a concurrent infection. (see Figure 1, next page)

#### Anaphylaxis

A two month old calf in good condition died 30 minutes after vaccination. There was white froth at the nostrils and mouth, tracheal froth and pulmonary oedema. No other significant gross pathology was detected, bacteriology results were unremarkable and vitreous humour calcium and magnesium levels and kidney lead level were within normal limits. Anaphylaxis was considered as a likely cause of death. Suspect adverse reactions should be reported to the Veterinary Medicines Directorate.

[www.gov.uk/report-veterinary-medicine-problem/animal-reacts-medicine](http://www.gov.uk/report-veterinary-medicine-problem/animal-reacts-medicine)



**Figure 1**

Otitis media due to *Mycoplasma bovis*. Caseous necrosis in the tympanic bullae demarcated by yellow and black arrows.

#### Alimentary diseases

##### Ruminal obstruction

A large volume of plastic wrap was found in the rumen of an emaciated four-year old Friesian suckler cow. The plastic wrap weighed 30 kg and filled most of the rumen volume. The wrap was of the type used to wrap round bales of silage. It was considered likely that the wrap had interfered with consumption of feed, rumination and digestion so as to cause the emaciation

**Figure 2**

Plastic wrap filling the rumen of a 4 year old cow.

### Neonatal enteritis

The pathogens identified in neonatal bovine faecal samples during the quarter are shown in Table 1. Overall, *Cryptosporidium* species and rotavirus were the most common pathogens identified.

TABLE 1: Pathogens identified in neonatal bovine faecal samples in Northern Ireland, January to March 2018

Pathogen	Number	
	Tested	Positive ( per cent)
<i>Cryptosporidium</i> species	344	131 (38.1%)
Rotavirus	339	104 (30.7%)
Coronavirus	341	33 (9.7%)
<i>Escherichia coli</i> K99	241	6 (2.5%)

### Other enteric conditions

Parasitic ova found in ruminant faeces samples submitted during the period are shown in Table 2.

Table 2: Endoparasitic infections in ruminants in Northern Ireland, January to March 2018

	Total	No of parasitic ova					% positive
		Negative	+	++	+++	++++	
Liver fluke							
Bovine	553	464	71	16	0	2	16.1%
Ovine	746	622	40	39	6	39	16.7%
Paramphistome							
Bovine	553	209	62	140	53	89	62.2%
Ovine	745	492	94	112	20	27	33.9%
Coccidia							
Bovine	660	568	82	4	1	5	13.9%
Ovine	757	268	476	8	3	2	64.6%
Strongyle worm egg count	Total	<500 epg	≥500 epg				% Positive
Bovine	657	651	6				0.9%
Ovine	756	675	81				10.7%

≥500 eggs per gram of faeces (epg) was considered of likely clinical significance  
+ Low, ++ Moderate, +++ High, ++++ Very high

### Johne's disease

Examination for *Mycobacterium avium* subspecies *paratuberculosis* (MAP) was carried out by microscopic examination, with Ziehl-Neelsen staining, on 157 bovine faecal samples. Forty-four samples (28 per cent) contained acid-fast organisms typical of MAP. Of 5017 bovine blood samples that were tested for antibodies to MAP 385 (7.7 per cent) were positive.

### Reproductive and mammary diseases

#### Abortion

Specimens from 130 bovine abortions and stillbirths were examined during the 1st quarter. Significant pathogens were detected in 64 cases (49.2 per cent). Of these, *Trueperella pyogenes* (17 cases, 13.1 per cent) was the most commonly identified pathogen. Other pathogens identified included *Bacillus licheniformis* (15 cases, 11.5 per cent), bovine viral diarrhoea virus (7 cases, 5.4 per cent), *E coli* (6 cases, 4.6 per cent),



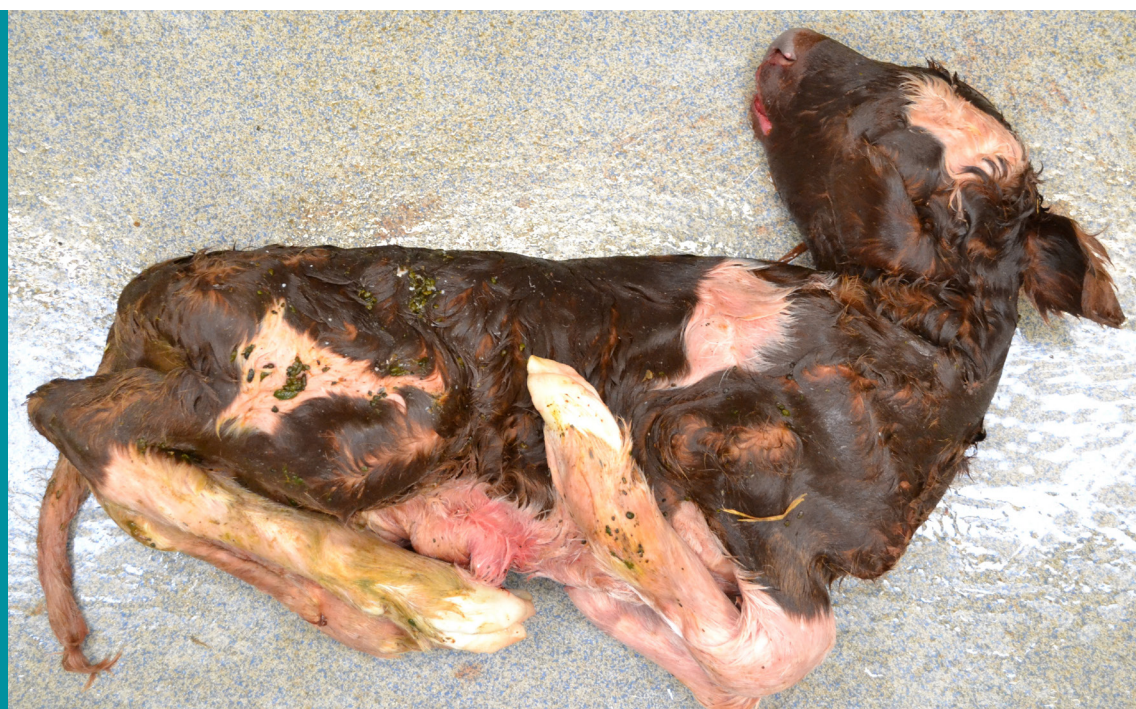*Leptospira* spp. (5 cases, 3.8 per cent), *Neospora caninum* (4 cases, 3.1 per cent) and Schmallenberg virus (1 case, 0.8 per cent).

### Abortion due to *Ureaplasma*

Two cows aborted 4-6 weeks before the due calving date. No potentially abortifacient microorganisms were identified by culture or serologically, but histologically the lungs of both foeti showed lymphocytic bronchiolitis, presence of small peribronchiolar lymphocytic accumulations, small parenchymal lymphocytic follicles and expansion of the alveolar walls by round cells. The lung histology in each case was considered suggestive of *Ureaplasma* sp infection. Ureaplasmosis is a sporadic cause of abortion in cattle. Frequently there are no gross lesions to be detected in the foetus but there is often a placentitis.

### Deformities due to Schmallenberg virus

Schmallenberg viral nucleic acid was detected by PCR in tissue of an aborted bovine foetus which presented with multiple skeletal abnormalities including kyphosis, torticollis and arthrogryposis. Antibody to Schmallenberg was detected in foetal fluid. These findings were considered to support a diagnosis of foetal abnormalities due to transplacental infection with Schmallenberg virus.



**Figure 3**

Skeletal deformities in an aborted calf caused by Schmallenberg virus.

### Mastitis

A total of 155 bacterial isolates were cultured from milk samples submitted from acute and chronic mastitis cases. Five (3.3 per cent) samples yielded cultures of more than two organisms and were considered to be potentially contaminated. No bacteria were cultured in a further 38 samples. *E coli* was the most frequently isolated organism and accounted for 23.7 per cent of isolates cultured. Other frequently identified organisms included, *Streptococcus uberis* (11.8 per cent), *Staphylococcus aureus* (7.2 per cent), non-haemolytic *Staphylococcus* species (6.6 per cent), *Bacillus licheniformis* (5.5 per cent), *Streptococcus dysgalactiae* (5.8 per cent) and alpha-haemolytic streptococci (4.5 per cent).

### Neurological diseases

*Clostridium botulinum* type D toxin was diagnosed in two cases during the 1st quarter of 2018 by the culture ELISA technique.

## Other diseases of cattle

### Calf diphtheria

Several cases of calf diphtheria were diagnosed. In one case in a three week old calf *Fusobacterium necrophorum* was cultured from a large ulcerated lesion on the underside of the tongue and from a suppurating navel.

### Salmonellosis

Septicaemia due to *Salmonella* Dublin was diagnosed in two two-week-old calves. One calf appeared septicaemic, there was a yellow hue of the carcass and blood appeared thin and watery. There was a fibrin clot in the anterior chamber of the eye of the second calf, ischaemic necrosis of the ear tips and swollen dark red and oedematous hindlimbs distal to the fetlock (probably early gangrenous change). *Salmonella* Dublin was cultured in septicaemic distribution from both calves.

### Mycotic pericarditis and myocarditis

A severe mycotic pericarditis and myocarditis was diagnosed histologically in a 5 day old calf. There were also lesions of mycotic pneumonia. There was navel ill and milky fluid in the rumen and reticulum. The zinc sulphate turbidity test revealed severe hypogammaglobulinaemia and it was considered that this likely predisposed to the systemic fungal infection.

## SHEEP:

### Respiratory diseases

Respiratory disease was identified in 20 ovine post mortem submissions during this quarter. Jaagsiekte (eight cases), *Mannheimia haemolytica* (four cases), *Bibersteinia trehalosi* (one case) and *Pasteurella* sp. (one case) were the most common diagnoses.

### Johne's disease

Five ovine faecal samples were examined microscopically using Ziehl-Neelsen staining for MAP. Four samples (80 per cent) contained acid-fast organisms typical of MAP. 5 ovine bloods samples were tested for antibodies to MAP during this quarter, one (20 per cent) of which was positive.

Two cases of Johne's disease were diagnosed on postmortem examination. A case of Johne's disease was diagnosed in a two-three year old ewe. The caecal wall was thickened and congested. Numerous acid fast bacilli were detected in a faecal smear, antibody to *Mycobacterium avium paratuberculosis* was detected in serum and the diagnosis was confirmed histologically with severe granulomatous enteritis and very abundant acid fast bacilli in the mucosa and submucosa.

### Fungal infection

Severe necrotizing hepatitis, abomasitis and reticulorumenitis was diagnosed in a two year old hogget, one of four affected. Very abundant fungal hyphae were present in histological sections of abomasum, reticulum and liver.

### Intestinal adenocarcinoma

A seven-year-old pregnant ewe died with frothing at the mouth. At post-mortem examination the liver was found to be pale and had a greasy texture. The serosa and mucosa of the terminal duodenum, jejunum and proximal ileum was diffusely thickened. The serosa had a "ground glass" appearance and the mucosa was hyperaemic. Histologically the small intestine showed ovine intestinal adenocarcinoma, with solid sheets and whorls of poorly differentiated cuboidal and columnar cells arranged in scattered irregular acini. There was infiltration of the submucosa, muscularis layer and serosa with islets of tumour cells forming irregular acini in the midst of an extensive desmoplastic reaction. There was a marked lymphocytic reaction in some areas of the mucosa. There was fatty infiltration of the liver parenchyma. Intestinal adenocarcinoma with secondary fatty liver was diagnosed.

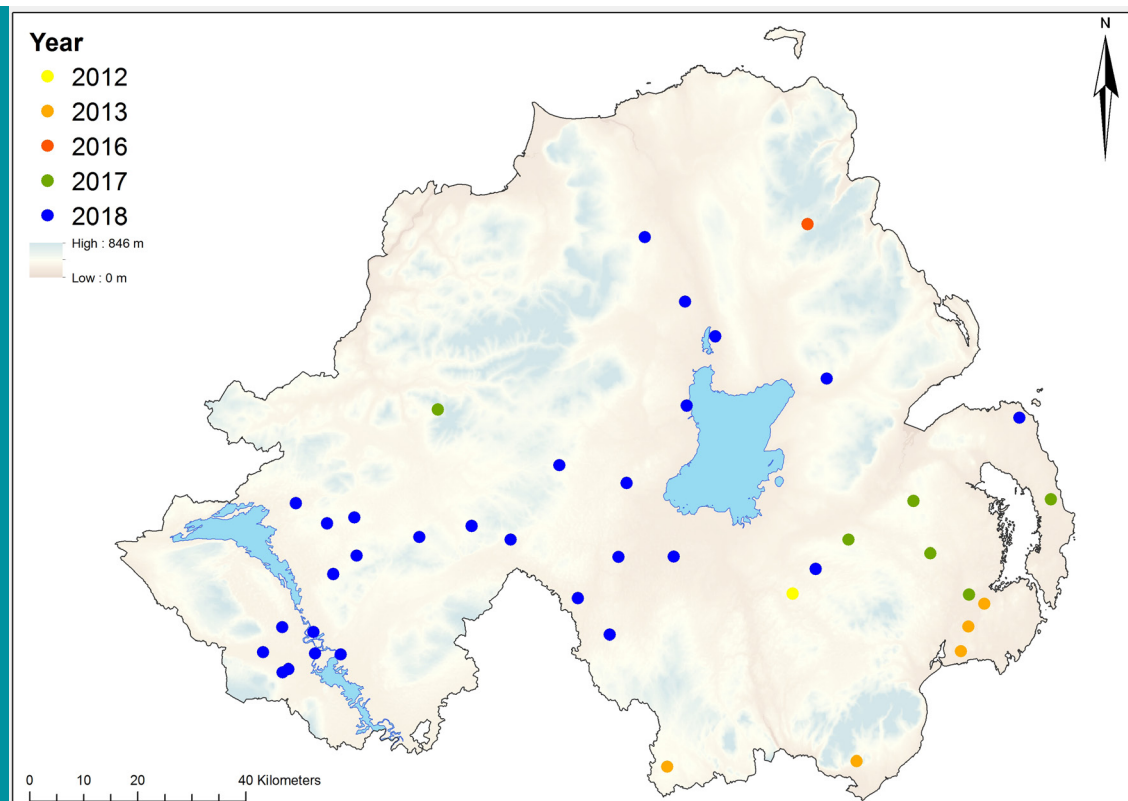


## Reproductive diseases

Specimens from 243 ovine abortions and stillbirths were examined during the 1st quarter of 2018. The pathogens identified were *Toxoplasma* (64 cases, 26.3 per cent), *Chlamydophila* (29 cases, 11.9 per cent), Schmallenberg virus (28 cases, 11.5 per cent), *E coli* (19 cases, 7.8 per cent), *Campylobacter* (9 cases, 3.7 per cent), *Trueperella pyogenes* (8 cases, 3.3 per cent), and *Listeria* (7 cases, 2.9 per cent).

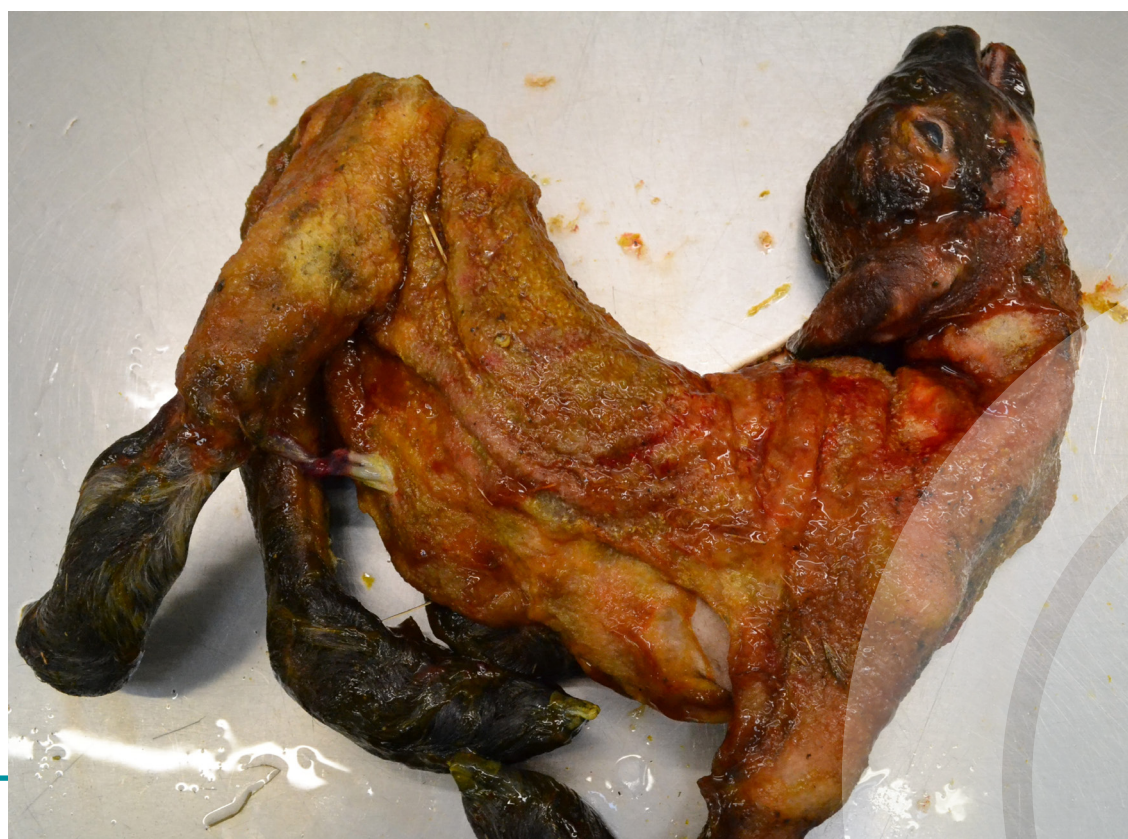## Schmallenberg

Twenty eight cases of abortion and stillbirth due to Schmallenberg virus were detected in the quarter with foeti presenting with arthrogryposis, torticollis, kyphosis, scoliosis and neurological deformities. The geographical range in which cases of Schmallenberg infection were identified noticeably expanded with cases now confirmed in western counties of N Ireland in which SBV had not previously been detected.



**Figure 4**

Diagnosis of Schmallenberg infections of ovine and bovine foeti in N Ireland from 2012 to 2018. (Dots are for graphical representation only and are not indicative of the specific locations of farms)



**Figure 5**

Schmallenberg virus associated skeletal abnormalities in an ovine foetus

### Salmonellosis

*Salmonella* Agama was isolated in pure culture from the placenta and stomach contents of six aborted lambs submitted from the same premises. *S. Agama* is associated with abortion in sheep, and enteric disease may also occur. Wildlife reservoirs of the organism are important. Lambing-shed hygiene, prompt disposal of abortion material and separation of aborted ewes are vital to control.

### Yersiniosis

*Yersinia pseudotuberculosis* was isolated in pure culture from the stomach contents of a lamb that had been aborted 3-4 weeks before the due lambing date. The liver was visibly much enlarged, with conspicuous mottling. Histologically there was congestion, multifocal hepatoparenchymal necrosis with associated toxically modified inflammatory reaction and severe necrotising multifocal placentitis. Serologically the lamb had a low titre of antibodies to *Toxoplasma*, although the dam had been vaccinated.

### Ovine abortions secondary to chronic fascioliasis

Forty ewes out of a batch of 60 aborted over a period of several weeks. The cause of the abortions was not determined on examination of aborted foeti submitted on multiple occasions. Several foeti submitted had periventricular white matter degeneration. Two ewes which died in the periparturient period were submitted from the same flock and had severe liver damage due to chronic fascioliasis. It was considered likely that metabolic deficit due to heavy liver fluke burden led to the abortions.

### Neurological diseases

Clostridial enterotoxaemia was diagnosed in a two week old lamb. On gross postmortem examination there was profuse amber pericardial effusion containing a gelatinous fibrin clot and there was coning of the cerebellum. On histological examination of brain there was pericapillary pooling of proteinaceous fluid. Clostridial epsilon toxin was detected in small intestinal content.

### GOATS:

A four-year-old female goat was found dead with blood around the anus and perineum. It had been kept indoors on meal, and all vaccinations were stated to be up-to-date. At gross post-mortem examination evidence of enteritis and typhlitis was noted. There was focal distension of the distal small intestine associated with loss of muscle tone in the intestine wall. Histologically there was congestion and superficial necrosis of the intestinal mucosa with haemorrhage and associated presence of numerous rod-shaped bacteria. Large numbers of *Clostridium perfringens* were isolated in anaerobic culture. Clostridial enterotoxaemia was considered to be the likely diagnosis.

### HORSES:

102 swabs were examined for the presence of *Tayorella equigenitalis* during this quarter, all were negative. One hundred and eighteen swabs were cultured from horses with a history suggestive of strangles during this quarter, *Streptococcus equi* subspecies *equi* was isolated from one swab

### Alimentary obstruction

A four-week-old foal that had been kept indoors with its dam, and fed haylage, was found dead. At gross post-mortem examination a bolus of woody, fibrous material was found obstructing the mid-jejunum. Proximal to the obstruction, the intestine was dilated with straw-coloured fluid and a little fibre; distal to the obstruction the intestine was very congested with scant bloody content. Further distally the jejunum, ileum, caecum and colon were pale and collapsed.

### PIGS:

#### Reproductive diseases

Abortion due to parvovirus was diagnosed in porcine foeti. The foeti were submitted from a sow which was the fifth sow to abort in the period of a month.

### Endocarditis

Vegetative endocarditis was diagnosed on post-mortem examination of 3 fattening pigs. In each pig there were vegetative crumbly irregular masses with necrosis on the left atrioventricular valves. *Erysipelothrix rhusiopathiae* was cultured from the lesions.

### AVIAN:

At gross post-mortem examination of a three year old rooster from a back-yard flock, evidence was found of chronic pericarditis and there was inspissation of the gizzard, proventriculus and proximal intestine. A heavy *Capillaria* burden was detected.