

Highlights:

- Infectious bovine rhinotracheitis and *Mycoplasma bovis* pneumonia in calves.
- Persistent bovine viral diarrhoea virus infection in calves.
- Infectious laryngotracheitis infection in backyard poultry.
- *Mycobacterium bovis* in a cat.

CATTLE

Respiratory diseases

Pneumonia was identified as the cause of death in 99 carcass submissions between January and March 2006. *Mannheimia haemolytica* (11 cases), *Mycoplasma bovis* (11 cases), *Pasteurella multocida* (10 cases), *Histophilus somni* (4 cases) and bovine respiratory syncytial virus (BRSV) (3 cases) were the most common pathogens isolated. One case of pulmonary thromboembolism was identified. A seven year-old cow, which had calved 4 months previously, was submitted in February for postmortem examination after an illness of several weeks duration. At necropsy there was vegetative endocarditis of the pulmonary valve with pulmonary thromboembolism.

A five-month-old female calf was submitted for postmortem examination in February after a period of treatment for pneumonia. The carcass was jaundiced and anaemic and there were petechial hemorrhages over the epicardium, omentum and the serosal surfaces of the

abdominal viscera. *Pasteurella multocida* was isolated from pneumonic lesions. The detection of bovine viral diarrhoea virus (BVDV) antigen in the lung and spleen suggested that the bacterial infection was probably secondary to immunosuppression caused by BVDV infection.

An outbreak of respiratory disease was investigated in January. At least 10 six-month-old calves from a housed group of 75 were affected. A calf, which was submitted for postmortem examination, had been recumbent for 2-3 days prior to death. A resolving tracheitis and a severe subacute pneumonia were observed at necropsy. Infectious bovine rhinotracheitis virus (IBRV) was detected in trachea and lung and *Mycoplasma bovis* was detected in lung.

Alimentary diseases

BVD / Mucosal disease

A total of 161 blood samples were tested by virus isolation or antigen capture ELISA for BVD virus. Of these, a positive result was obtained from 40 samples (25%). In addition 557 submitted tissues and nasal mucus samples were tested by immunofluorescence for BVD virus, with 25 (4%) being found positive.

Five cases of mucosal disease were confirmed at postmortem examination during this quarter. In one case, a 9-week-old calf in poor condition was euthanased after numerous recurrences

of diarrhoea. BVDV was isolated from spleen, mesenteric lymph node and blood. No BVDV antibodies were detected in serum from this calf. Another two-day-old calf with BVDV infection was hypogammaglobulinaemic. It was therefore unclear whether the dam was persistently infected with BVDV. It was recommended that a blood sample be taken from the dam to investigate this possibility.

A blood sample was submitted in February from a calf whose twin had previously been diagnosed as persistently infected with BVDV. Tests revealed that this calf was also persistently infected with BVDV.

Blood samples submitted from a batch of 7 calves in January revealed three animals persistently infected with BVDV with the other 4 demonstrating seroconversion to this virus.

Blood samples for screening were submitted from a bull, which was to be sent to an AI station. This animal was positive for BVDV on virus isolation but serologically negative. In addition it was seropositive to IBRV. The bull was refused access to the AI station. This case emphasises the importance of disease screening before using bulls in any breeding programme.

In another case, blood samples were submitted in January from 4 poorly thriving calves less than 12 months old and two bulls purchased within the previous 15 months. The bulls from this farm were seropositive, indicating post-natal exposure. All 4 of the calves were virus-positive but antibody-negative, consistent with persistent infection.

Neonatal enteritis

Six hundred and one faeces samples were tested for rotavirus with 135 (22%) found positive. Five hundred and ninety-three faeces samples were tested for coronavirus, with 9 (2%) found positive. Six hundred and thirty faeces samples were tested for *Cryptosporidium*, with 234 (37%) positive. Two hundred and twenty seven faeces samples were tested for *E. coli* K99 with 12 (5%) positive.

Faecal and blood samples were submitted in February from two calves on a farm with a history of calves scouring at a few days of age. The calves were bought in from a dairy herd at one-day-old. Pooled colostrum was also purchased from the same farm and fed to the calves. Blood from one calf had a zinc sulphate turbidity (ZST) level of 12 indicating inadequate colostrum antibody absorption. *E. coli* expressing the K99 antigen was isolated from a faecal sample from this animal. *In vitro* antibiotic sensitivity tests revealed this isolate to be resistant to all antibiotics in the panel except ceftiofur. The other calf showed adequate colostrum antibody absorption (ZST of 20) and no significant pathogens were isolated from the faeces sample from this calf.

Other enteric conditions

Parasitic ova found in ruminant faeces samples submitted during the period are shown in Table 1.

A two-month-old calf that had shown neurological signs, including teeth grinding, was submitted for postmortem examination in January. Gross and histological evidence of abomasal

ulceration with significant bleeding into the gastrointestinal tract, was found. There was also an acute rumenitis associated with a heavy presence of unidentified rod-shaped bacteria and *Candida* infection.

A 10-year-old cow was submitted for postmortem examination in January. The rumen was greatly distended with dry ingesta and a pedunculated vegetative polyp-like mass of tissue was found in the rumen attached to the rim of the oesophageal inlet. The position of this tissue mass was such that regurgitation, but not ingestion, would likely have been compromised. Prevention of cudding would also have substantially reduced the flow of saliva to the rumen.

A four-year-old cow was submitted in February having died after a period of losing condition and drooling saliva. At postmortem examination the pericardial sac was massively distended by fibrin and fluid, with thick fibrinous exudates adhering to the epicardium and pericardium. The presence of a fibrous tract, containing a 7cm long piece of thin wire connecting the pericardial sac to the reticulum through the diaphragm, confirmed this as a case of foreign body pericarditis.

Faecal samples submitted in February for routine screening from an organic herd revealed the presence of fluke eggs in 3 of 6 samples.

Table 1

Endoparasitic infections in ruminants in Northern Ireland, January to March 2006

Number			Number of parasites					Percentage positive
	Total	Negative	With > 800 epg*	+	++	+++	++++	
Liver fluke								
Bovine	420	335		61	20	4	0	20.2%
Ovine	86	63		10	3	2	8	26.7%
Coccidia								
Bovine	562	448		93	10	7	4	20.3%
Ovine	107	54		43	5	4	1	49.5%
Strongyle worm egg count								
Bovine	472		12					2.5%
Ovine	87		17					19.5%

- > 800 eggs per gram of faeces (epg) was considered of likely clinical significance
- + Low, ++ Moderate, +++ High, ++++ Very high

Johne's disease

Examination for *Mycobacterium avium* subspecies *paratuberculosis* (MAP) was carried out by microscopic examination (Ziehl-Neelsen staining) on 230 bovine faecal samples. Sixteen samples (7%) contained acid-fast organisms typical of MAP.

A total of 1758 bovine blood samples were tested for antibodies to MAP. One hundred and three samples (6%) tested positive.

Nutritional and metabolic diseases

Three two-week-old calves from a group of 32 were submitted for postmortem examination in February. Eight of these had become recumbent and died despite supportive therapy including intravenous and oral electrolyte fluids. The clinical signs had begun 36 hours after a sudden and complete change of diet from whole milk to UHT whipping cream (intended for human consumption, but rejected because of poor whipping characteristics), which was diluted one part in three parts water. Postmortem examination of the three deaths submitted revealed enteritis in the absence of any significant enteric pathogens. Blood samples taken prior to treatment revealed hypocalcaemia and hyperphosphataemia with elevated urea levels. Other calves in the batch, which were dull but not recumbent, returned to normal after receiving one feed of oral electrolytes followed by return to a diet of whole milk. The herdowner was advised to feed the cream in a concentration approximating more closely to the fat content of whole milk, but he decided not to use the by-product again.

A blood sample was submitted in March from one of three recumbent cows. All three were due to calve in one month and the sample submitted revealed hypomagnesaemia (0.3 mM/L, normal range 0.73-1.31 mM/L).

Reproductive and mammary diseases

Abortion

Specimens from 126 bovine abortions were examined between January and March 2006. Pathogens associated with bovine abortion were detected in 52 cases (41%). Of these *Leptospira* Hardjo was the most commonly identified pathogen, being detected in 18 cases (35%). *Bacillus licheniformis* was cultured from 7 cases (13%), *Neospora caninum* infection was diagnosed in 5 cases (10%) and *Salmonella* Dublin was cultured from 3 cases (6%). One foetus submitted in February yielded a pure growth of *Pasteurella multocida* from abomasal contents. Specimens from three aborted foetuses were submitted in January from a dairy herd where there had been five abortions within one week. Leptospiral antigen was detected in all three foetuses and neospora antibody was detected in the foetal fluid from one. Twelve blood samples were submitted in February from cows that had aborted in this herd. Eight of the 12 samples were seropositive for *Neospora caninum* and 5 cows had *Leptospira* Hardjo titres ranging from 1/30 to 1/300.

A semen sample was submitted for culture from an AI bull in January. Purulent material had been noted in the bull's ejaculate several months previously. The condition had then responded to

antibiotics but subsequently relapsed. At the time of submission of the samples the bull had not been treated with antibiotics for approximately 6 weeks and was in good general health, with no swelling or pain in genital organs or accessory glands. A mixed growth of *Histophilus somni* and *Arcanobacterium pyogenes* was cultured from the semen sample. A guarded prognosis with a recommendation for a prolonged period of treatment with a suitable antibiotic was given. Both isolates were sensitive to all the antibiotics in the *in vitro* panel.

Mastitis

A total of 1122 bacterial isolates were cultured from milk samples submitted from acute and chronic mastitis cases. Fifty-three (4.7%) samples yielded cultures of more than two organisms and were considered to be potentially contaminated. No bacteria were cultured in a further 504 samples. Coliforms were the most frequently isolated organisms and were present in 19.3% of samples where microorganisms were identified. *Streptococcus uberis* was cultured in 12.4% of samples, while *Staphylococcus aureus* was isolated in 9.9% of samples. *Streptococcus dysgalactiae* was cultured from 4.6% of samples and *Streptococcus agalactiae* was cultured from 2 cases (0.2%).

Nervous diseases

A six-week-old calf was submitted in March from a unit where there had been a few recent deaths in young calves at grass. Although the submission history was of sudden death of a healthy calf, postmortem examination revealed that

the calf had been diarrhoeic and was in very poor body condition. A large cerebral abscess, from which *Fusobacterium necrophorum* was recovered, suggested a previous septicaemia. Low numbers of coccidial oocysts were also present in intestinal contents. Another calf from the same unit had evidence of navel infection and joint ill.

Clostridium botulinum type D toxin was detected in liver, small intestine contents and faeces from one bovine submission that had a history of suspected botulism.

Other diseases

A six-week-old Simmental calf was submitted for postmortem examination in February with a history of dyspnoea and death within 24 hours. At postmortem examination the heart was massively dilated with an 8cm diameter ventricular septal defect (Figure 1). Passive congestion of the liver and copious serous abdominal fluid were also present.

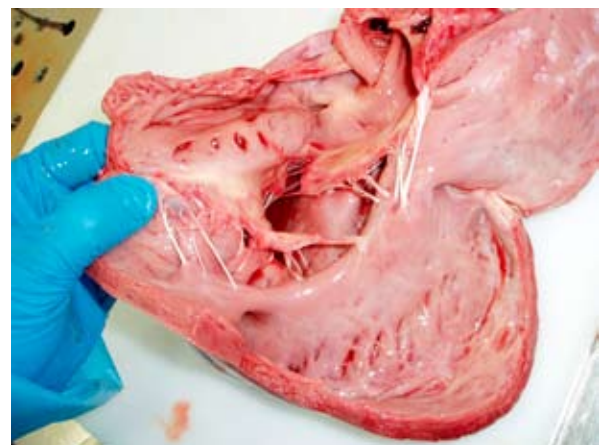


Figure 1
Ventricular septal defect in a simmental calf

An eye swab taken from a three-year-old cow with a history of bilateral uvetitis was submitted for culture in January. A pure culture of *Listeria monocytogenes*, which was sensitive to all antimicrobials in the *in vitro* panel, was isolated.

A 9-month-old bullock, with a history of ill thrift, was submitted for investigation in February. At postmortem examination there was a large vegetative mass on the left atrio-ventricular valve, with multiple purulent foci in the myocardium (Figure 2) and lung parenchyma. A purulent arthropathy in the carpal joints was also present.

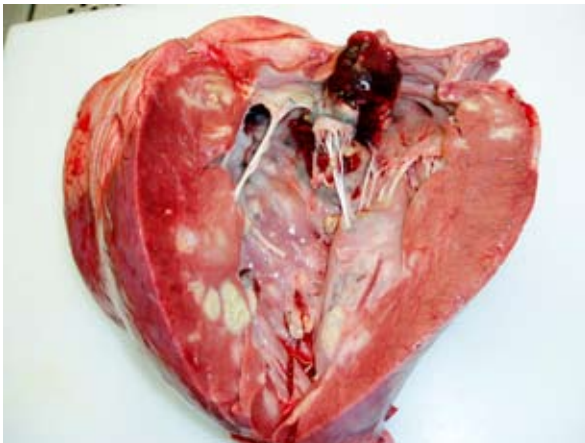


Figure 2
Myocardial abscesses in a nine month old bullock

A 9-month-old bullock, which had persistent diarrhoea and hind limb paralysis, died in January. The animal was febrile (103-105°F) and also had a nasal discharge. At postmortem examination a severe chronic, active endocarditis was observed which involved the left atrio-ventricular valve and extended deeply into the surrounding myocardium. No bacteria were recovered from the heart.

A two-month-old calf was submitted for postmortem examination in February with a history of sudden death. Lesions

typical of blackleg were observed in the tongue and positive fluorescence for *Clostridium chauvoei* was observed in tongue muscle.

SHEEP

Reproductive diseases

Samples from 249 ovine abortions were examined during the first quarter of 2006. Recognised pathogens were detected in 186 cases (75%). Of these, chlamydial abortion (EAE) was detected in 59 cases (32%), toxoplasmosis was detected in 43 cases (23%) and leptospirosis was detected in 30 cases (16%). In one case an aborted foetus was submitted in February from a flock 4-6 weeks prior to the expected lambing date. There had been 4 abortions within the previous 10 days and a pure, profuse culture of *Listeria ivanovii* was recovered from multiple organs.

Three serum samples were submitted in January from ewes, which had recently been scanned and found to be carrying dead lambs. All three had significant toxoplasma titres, but one animal had a very high *Leptospira* Hardjo titre of 1/10,000. A further twelve blood samples taken subsequently from ewes which had aborted in this flock revealed significant toxoplasma titres in five ewes and L. Hardjo titres varying from 1/10 to 1/1000 in six ewes. Two samples also demonstrated seroconversion to chlamydia (EAE). L. Hardjo was cultured at post-mortem examination of the ewe, which had earlier demonstrated a L. Hardjo titre of 1/10,000.

In another case, eight blood samples were submitted in January from a flock with an abortion problem. Titres to L.

Hardjo ranging from 1/100 to 1/300 were detected in seven of the eight samples. Five of the samples also had significant toxoplasma titres.

Nutritional and metabolic diseases

An eleven-month-old fattening ram lamb was submitted in January from a flock in which there had been three other deaths. The lambs had been housed for two months on a diet of meal and silage. Postmortem examination revealed excess abdominal fluid and extensive peritonitis. A ruptured bladder containing numerous calculi was seen. Appropriate management changes to prevent urolithiasis were recommended.

A two-year-old Texel ewe was submitted in March with a history of sudden onset of ataxia, inappetance, jaundice and haematuria. The recent diet was reported to have consisted of sheep meal and pasture. Postmortem examination revealed a jaundiced carcass and a bronze-coloured liver with tissue copper levels of 580 ug/g detected in the liver and 100 ug/g in the kidney. Analysis of a sample of meal revealed copper levels of 9.9 ug/g dry matter. The recommended inclusion level for copper in sheep feed is <12 ug/g DM. No information was available on the copper, molybdenum, sulphur or iron levels in the forage being fed.

Alimentary diseases

Salmonella enterica subsp. *diarizonae* was cultured from the large and small intestines of a ewe submitted in January with a history of sudden death. The ewe was at pasture and had been fed meal

in a trough with 22 other ewes. Isolation of *Salmonella enterica* subsp. *diarizonae* from sheep is rare in Northern Ireland. It is thought that contamination of the feeding trough with wild bird faeces is the most likely source of infection.

E. coli O157 was cultured from viscera submitted from a lamb in March. Appropriate public health advice was given.

Two ewes were submitted in March from a flock that had a problem of ewes losing condition and dying; up to 10 deaths were reported. At postmortem examination, both sheep had severe, subacute liver fluke burdens. The flock had been dosed three times in the previous three months. Triclabendazole had been used on at least two occasions, suggesting the possibility of drug resistance.

Johne's disease

A total of seven ovine faecal samples were examined microscopically (Ziehl-Neelsen staining) for *Mycobacterium avium* subspecies *paratuberculosis* (MAP). Two samples contained acid-fast organisms typical of MAP. The remainder of the samples were negative.

A total of 18 ovine blood samples were tested for antibodies to MAP. One sample tested positive.

A three-year-old ewe with a history of ill thrift and scouring was submitted for postmortem examination in February. Two other sheep in the flock had died recently with similar signs. At necropsy the small intestinal contents were watery while the mucosa of the mid- and distal small intestine was irregularly thickened and regionally pigmented yellow.

Histologically the small intestinal mucosa was infiltrated by macrophages, which were distended by numerous acid-fast bacilli, confirming a diagnosis of Johne's disease.

Respiratory diseases

Pneumonia was identified as the cause of death in 13 ovine carcass submissions during the first quarter of 2006.

Mannheimia haemolytica was the most common cause, having been diagnosed in 6 cases. Laryngeal chondritis and necrotising laryngitis were observed in one 4-week-old lamb submitted in March. *Mannheimia haemolytica* was cultured from abscesses in both arytenoid cartilages.

Nervous diseases

Eight cases of listeriosis were confirmed by postmortem examination during the first quarter of 2006. All cases were confirmed by the presence of typical histopathological changes in the brainstem (microabscessation).

A three-year-old Texel ram was submitted for postmortem examination in March. At necropsy a lesion was found in the spinal canal that was suggestive of 'wobbler' syndrome. This lesion comprised herniation of intervertebral disc material into the spinal canal, causing constriction of the cord. Histological examination of the spinal cord from the affected region revealed Wallerian degeneration caused by tissue pressure.

Two eight-month-old fattening lambs were submitted in January with a history of neurological signs including opisthotonus. Four of 60 lambs had

died in the previous three days. One lamb had urolithiasis, ruptured bladder and uroperitoneum. The other lamb had localised focal gliosis and perivascular cuffing in the cerebrum. Both brain and heart were strongly positive for *Toxoplasma* cysts by immunoperoxidase labelling.

Skin diseases

Wool samples from six flocks were examined for sheep scab mites.

Psoroptes ovis mites were observed in samples from 4 flocks.

Other diseases

Two four-day-old lambs were submitted in February from a flock with a high incidence of joint-ill. Lambs were born healthy, becoming stiff and recumbent with death following a few days later. Arthritis due to *Streptococcus dysgalactiae* was detected at postmortem examination. This organism causes arthritis in lambs under 4 weeks of age. Lambs usually acquire the infection from environmental sources (pens, paddocks) in the first two weeks of life. Some ewes within a flock may carry these bacteria in the vagina and are probably responsible for the original environmental contamination. Attention to environmental hygiene, navel dipping and disinfection of stomach tubes used for colostrum administration are important issues to address in the face of an outbreak.

GOATS

A skin from a goat was submitted for examination in January. This skin had been cured and dried and was

intended to be used in the preparation of a large traditional drum. Examination revealed multifocal raised nodules containing caseous material. Histological examination of sections of the lesions revealed the presence of *Demodex* mites, confirming a diagnosis of follicular demodicosis. *Demodex spp* live as commensals in the skin of most mammals. The pathogenesis and epidemiology of demodicosis has been widely documented in the dog and is similar in other mammalian species. Initial lesions on the face and neck of goats extend to the chest and flanks and may eventually involve the whole body with the formation of cutaneous nodules containing yellow caseous material. Demodicosis in goats is rarely debilitating and is of importance as a cause of downgrading or condemnation of goatskins.

Faeces samples were submitted in January from 2 goats with dysentery. Several goats in the herd had died suddenly over the previous few days. *Clostridium perfringens* was isolated and tests for epsilon and alpha toxins were positive for both samples suggesting *C. perfringens* type D, as the cause of enterotoxaemia in these adult goats. An abrupt change in diet or overeating, especially on energy-dense foods, may predispose to enterotoxaemia.

PIGS

Porcine circovirus infection was confirmed in several submissions for postmortem examination during the first quarter of 2006. A one-month-old pig was submitted in March from a unit where there had been five deaths in the previous ten days in a group of fifteen weaned piglets. The submitted pig was

in good condition, the carcass was jaundiced and the liver was rounded, pale and friable. Histological examination revealed marked hepatocyte necrosis and many of the remaining hepatocytes were swollen and degenerating. A number of hepatocyte nuclei contained inclusion bodies. There was a limited associated inflammatory response consisting mainly of macrophages. Examination of porcine circovirus type 2 immunostained liver sections revealed widespread positive staining of hepatocytes and macrophages. The diagnosis was of acute post-weaning multisystemic wasting syndrome (PMWS). Hepatic pathology in PMWS is described in experimental studies but appears to be uncommon in natural infections.

BIRDS

Poultry

Two hens, which died in January, were presented for postmortem from a small backyard flock of 18-20 hens (mostly Rhode Island Reds and Malays). Approximately 25% of the flock had developed respiratory signs of serous nasal discharge and snuffle. At postmortem examination a mild tracheitis was detected in one bird with blood clots adherent to the tracheal mucosa. Infectious laryngotracheitis was confirmed by positive immunofluorescence and virus isolation in both birds.

Four male birds were submitted in January from a breeding unit where birds had been dull with swollen wattles. At necropsy, swollen, oedematous wattles with subcutaneous fibrin were observed. Profuse growths of *Pasteurella multocida* were recovered from the wattles.

Cage and Aviary

Histopathological examination of liver tissue from one adult Victoria crowned pigeon, submitted for postmortem examination, revealed evidence of an iron storage disorder. There was an accumulation of dense granular pigment in the hepatocytes, which stained positive for iron by Perl's stain. In addition, there were focal lesions of necrosis and inflammation in the myocardium, and a large amount of fluid was present in the pericardial sac.

Wild birds

Forty-five starlings found dead at a private residence were submitted for investigation in February. At postmortem examination there were haemorrhages into the body cavity and tears in the breast muscles with occasional rib fractures, which was consistent with trauma. It was suspected that a flock had collided with an obstruction, resulting in the injuries observed.

A householder reported increasing numbers of dead birds in his garden where he had a number of feeding stations. Greenfinches and chaffinches were submitted. The main post mortem finding was necrotic oesophagitis and one bird had necrotic foci in the liver and spleen. *Salmonella* Typhimurium was cultured in a septicaemic pattern from all cases.

All wild bird submissions were screened for avian influenza with negative results.

HORSES

Eight blood samples were submitted for serology for equine herpesvirus infection. Six samples from six separate premises were positive.

Material from five equine abortions was received during the quarter. A pure growth of *Streptococcus zooepidemicus* was cultured in a septicaemic pattern from one foetus. No significant pathogens were detected in the other four foetuses.

Twenty-six blood samples were tested for equine viral arteritis with one found positive by virus neutralisation test.

Five hundred and sixteen clitoral swabs were examined for the presence of contagious equine metritis organism prior to movement of mares to stud. All were negative.

Eighteen swabs were cultured from mares with a history suggestive of strangles. *Streptococcus equi* was detected in four samples from three separate premises.

WILDLIFE

Marine mammals

A porpoise submitted in January was one of two found dead together on a beach. The submitted porpoise was a young adult male in poor nutritional condition. At necropsy, it was found to have a heavy lungworm burden that would have been of clinical significance. It also had discospondylitis of the last thoracic vertebra; these are of no clinical significance. Although *Brucella* spp are frequently recovered from similar lesions, cultures in this case

were sterile. Histological examination of sections of brain tissue revealed a severe encephalitis. A viral aetiology was suspected but immunohistochemical labelling for Morbillivirus was negative.

OTHER SPECIES

Feline

A seven-month-old female pet cat was submitted for postmortem examination in March. The cat was in good condition and gross changes were confined to the lungs with multifocal raised lesions approximately 1-2 cm in diameter with purulent cores. Histological lesions consistent with feline tuberculosis were observed in H&E-stained sections of lung tissue and examination of Ziehl-Neelsen stained sections revealed large numbers of acid-fast rods within the necrotic areas. Liver, lung, spleen and small intestine were cultured and *Mycobacterium bovis* was isolated from all four samples confirming that this cat was infected with bovine tuberculosis.

This summary has been compiled by the Veterinary Sciences Division of the Agri-Food and Biosciences Institute (AFBI*) of Northern Ireland and is based on diagnostic submissions to AFBI's veterinary laboratories at Stormont, Belfast, and Omagh, Co Tyrone.

<http://www.afbini.gov.uk/index/services/diagnostic/adds.htm>

*AFBI was created on 1st April 2006 as the amalgamation of DARD Science Service and the Agricultural Research Institute of Northern Ireland. AFBI operates a farm animal disease diagnostic service on behalf of the Department of Agriculture and Rural Development for Northern Ireland.